


Contents lists available at [SciVerse ScienceDirect](http://SciVerse.Sciencedirect.com)

Seminars in Arthritis and Rheumatism

journal homepage: www.elsevier.com/locate/semarthrit

Malignant lymphoma in primary Sjögren's syndrome: An update on the pathogenesis and treatment[☆]

John G. Routsias, MD, PhD^{a,*}, John D. Goules, BS^b, Georgios Charalampakis, DMD^c, Sotiria Tzima, PhD^b, Aristeia Papageorgiou, MD^b, Michael Voulgarelis, MD, PhD^b

^a Department of Microbiology, School of Medicine, University of Athens, 75M Asias St, 11527 Athens, Greece

^b Department of Pathophysiology, School of Medicine, University of Athens, Greece

^c Institute of Odontology, University of Gothenburg, Sweden

ARTICLE INFO

Keywords:

Sjögren's syndrome
Non-Hodgkin lymphoma
Salivary glands
Autoimmunity
Lymphoproliferation

ABSTRACT

Objectives: Sjögren's syndrome (SS), a chronic autoimmune disorder, particularly compromises the function of exocrine glands. Its association with lymphoma is well documented. Our aim was to systematically review the molecular, clinical, histopathologic, and therapeutic aspects of these SS-related malignant lymphoproliferations.

Methods: The literature was searched for original articles published between 1968 and 2012 focusing on the risk factors for lymphoma development in Sjögren's syndrome using MEDLINE and PubMed. The search terms we used were "Sjögren's syndrome," "lymphoma," and "risk factors." All papers identified were English-language, full-text papers.

Results: A low-grade marginal-zone lymphoma related to mucosa-associated lymphoid tissue is the commonest lymphoid neoplasia in SS. The majority of SS-associated lymphomas are characterized by localized stage, indolent clinical course, and recurrence in other extranodal sites. Although the transition from a chronic inflammatory condition to malignant lymphoma is a multistep process that is yet poorly understood, there is increasing evidence that chronic antigenic stimulation by an exoantigen or autoantigens plays an essential role in the development of SS-associated lymphoproliferation.

Conclusions: This review discusses the pathogenetic aspects of lymphomagenesis in SS. Recent advances in the treatment of lymphoma in SS are also stated.

© 2013 Elsevier Inc. All rights reserved.

Introduction

Sjögren's syndrome (SS) is defined as a chronic, indolent, autoimmune disease, characterized by lymphocytic infiltration of the exocrine glands leading to their gradual destruction and resulting in dry mouth and dry eyes [1]. The syndrome may develop as an autonomous entity, in which case it is characterized as primary, or may coexist with other autoimmune diseases, such as rheumatoid arthritis (RA), systemic lupus erythematosus (SLE), or scleroderma (secondary). The incidence of non-Hodgkin's lymphoma (NHL) is higher in SS than in other autoimmune diseases [2,3] rendering this research model more than ideal in investigating the relationship between autoimmunity and lymphomagenesis. More specifically, according to a meta-analysis of 20 studies with different autoimmune diseases, aiming to evaluate the risk of lymphoma development, SS correlates with high risk for lymphoma development with a standardized incidence rate (SIR)

of 18.8% compared to moderate risk for SLE (SIR 7.5%) and low risk for RA (SIR 3.3%) [3]. Following this meta-analysis, another population-based case-control study in Denmark and Sweden, mapping autoimmunity disorders in 3055 NHL patients, concluded that risk for all NHL were increased in association with SS (odds ratio; OD 6.1) compared to other autoimmune diseases such as SLE (OD 4.6), RA (OD 1.5), and celiac disease (OD 2.1) [2]. It is believed that chronic antigenic stimulation, observed since the early stages of SS, triggers the mechanism of polyclonal B-cell activation. This, in turn, is responsible for the production of B-lymphocyte clones capable of inducing neoplasia [4]. In this regard, the risk of B-cell NHL in SS is associated with many parameters such as chronic hypocomplementemia, mixed monoclonal cryoglobulinemia, lymphocytopenia, palpable purpura, swollen salivary glands, lymphadenopathy, splenomegaly, and peripheral neuropathy [5,6].

B-lymphocytes dysregulation in Sjögren's syndrome

In normal B-cell differentiation after emigrating from the bone marrow (BM) to secondary lymphoid organs (SLOs), B-lymphocytes

[☆]Disclosure statement: The authors have declared no external funding.

* Corresponding author.

E-mail address: jroutsias@med.uoa.gr (J.G. Routsias).

give rise to transitional B-cells. These B-cells potentially mature into three B-cell subsets: CD5+ marker naïve B-cells, conventional naïve B2 cells (transitional type II B-cells), and marginal zone (MZ) cells that contain mutated immunoglobulin variable (IgV) genes probably acquired in a T-cell-independent manner. Naïve B-cells encounter antigens and produce high-affinity antibodies in critical SLO sites such as the spleen and lymph nodes [7]. Stimulation by antigens and the regulation by the B-lymphocyte activator of the TNF-family (BAFF) result in a proportion of transitional type II naïve B-cells migrating to the border between the T-zones and follicles (T:B border) in SLOs. During this process, autoreactive transitional type II B-cells encountering self-antigens undergo negative selection through apoptosis (peripheral check point) [8]. As a consequence, a restricted number of B-cells normally colonize each follicle and evolve as B blasts to fill the follicle. This process leads to the formation of germinal centers (GCs) within SLOs, observed as anatomically distinct dark and light zones on histologic sections. The dark zone comprises highly proliferating centroblasts and the light zone non-dividing centrocytes. The activation-induced cytidine deaminase (AICDA) that is responsible for somatic hypermutation (SHM) is triggered by centroblasts. This process is characterized by the introduction of single point mutations in hot spots within the IgV genes, which encode for the antigen-binding region of the antibody, providing affinity maturation of B-cell antigen receptor (BCR). Centrocytes bearing high-affinity BCR have the capacity to bind the antigen, which is presented by follicular dendritic cells (DCs). In association with help signals derived from T helper cells, this enables them to escape apoptosis and survive. Centrocytes also undergo class switch recombination (CSR), which affects the constant Ig region responsible for the effector capacity of the antibody. Selected centrocytes may further differentiate into memory B-cells or plasmablasts expressing mutated Ig with increased affinity for the immunizing antigen. The marginal zone (MZ) is located around the follicular mantle at the periphery of the splenic white pulp, as well as the periphery of lymphoid follicles. MZs accommodate B-cell populations of varied maturation stages; although functionally heterogeneous, these populations share the capacity for plasma cell differentiation, homing to certain tissue compartments, such as the Waldeyer's ring, Peyer's patches, and appendix, or other extranodal sites affected by chronic inflammation (MZ equivalents) [9]. Progression of transitional type II B-cells towards MZ or GCs may be determined by the quality of BCR-evoked signals and the subsequent expression of the Notch protein [10]. Human MZ B-cells of both spleen and Peyer's patches harbor mutated IgV genes and recirculate [11]. Human IgM+ CD27+ MZ B-cells, when compared to IgM+ CD27- naïve B-cells, appear to be selected against self-reactive BCRs [12]. This indicates that transitional type II naïve B-cells with self-reacting BCRs are efficiently excluded from the MZ B-cell pool before the onset of SHM (another peripheral check point).

In comparison to normal B-cell differentiation, two main autoimmune phenomena are observed in SS: (a) exocrine gland infiltration by populations of B- and T-lymphocytes and (Fig. 1) (b) excessive stimulation of B-lymphocytes, which not only secrete circulating autoantibodies against non-organ-specific autoantigens, such as the extractable nuclear and cytoplasmic antigens Ro(SSA) and La(SSB), but are also characterized by significant expansion of several (oligoclonal) or one (monoclonal) lymphocyte clones. In certain cases, this phenomenon is characterized by the presence of circulating monoclonal Ig light-chains and cryoprecipitating monoclonal rheumatoid factor (RF)-like immunoglobulins [13,14].

These particular B-lymphocytic infiltrates of the salivary glands are not only a morphological phenomenon. In the course of the disease they are associated with the formation of GCs, considered by many to be the first stage of development of NHL.

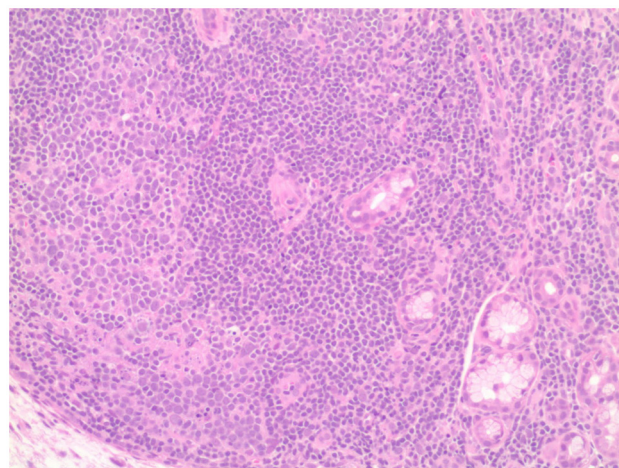


Fig. 1. Histopathological lesion in minor salivary glands of a patient with SS. The hallmark of SS is periductal lymphocyte infiltration of the salivary glands. In mild lesions, activated T-cells predominate, whereas B-cells prevail in severe histologic lesions [76].

There is evidence that the disorganized salivary epithelial cell in SS plays an active role in both induction of salivary gland inflammation and lymphoid-tissue neof ormation. Through apoptosis and formation of membrane-bound exosomes, salivary epithelium presents intracellular autoantigens such as Ro and La ribonucleoproteins, a process that prompts the breakdown of immune tolerance [15]. Epithelial cells have the capacity to function as antigen-presenting cells. For example, they express CD40 co-stimulatory and adhesion molecules and produce lymphoid chemokines, cytokines, and B-cell activating factors, all of which may induce recruitment of DCs, T-cells, and B-cells in the inflamed glands and the formation of ectopic lymphoid structures [15,16]. In this regard, the local environment promotes lymphoid organization by aberrant production of autoantigens and cytokines.

Ectopic formation of GCs in SS represents a complex process regulated by an array of cytokines, adhesion molecules, and chemokines. Several studies emphasize the importance of ectopic GC formation, concluding that this is a *sine qua non* of lymphoma development [17,18]. Consistent with that, a recent study suggests that the presence of GCs in SS is highly predictive marker for lymphoma development [18]. Interestingly, among SS patients, AICDA has been found to be invariably expressed within the follicular dendritic cell (FDC) network in the salivary glands [19]. This is highly significant since AICDA initiates both SHM and CSR [19]. Surprisingly, these GCs contain certain B-cells lacking the hallmark membrane markers for centroblasts and centrocytes (i.e., CD10 and CD38). Furthermore, there is no mantle zone in these GCs, suggesting that proliferating B-cells do not expand as within typical follicles, as occurs in SLOs. In these GC-like structures of salivary glands, B-cells harbor the CD20+, CD21+, CD23+, IgM+, and IgD+ profile, which is closer to that of transitional type II B-cells and marginal zone-like (MZ-like) B-cells. Therefore, we can conclude that while typical GCs are somewhat rarely found in salivary glands, these ectopic GC-like structures appear to correspond to the MZ-like equivalents [17,20,21]. It is yet unknown whether the T follicular helper (T_{fh}) cells that have been identified in the pathogenic lesion of SS are actually involved in the formation of GCs within the salivary glands.

Additional properties differentiating ectopic GC-like structures to normal GC include architectural and functional characteristics. Unlike common GCs, ectopic GCs in SS patients are not supplied by afferent lymph vessels nor are they encapsulated, which implies

their direct exposure to signals from the inflamed salivary gland environment, such as stimulating antigens and cytokines [22]. This incomplete development of ectopic GCs could incite the unrestricted access of DCs, lymphocytes, and macromolecules favoring abnormal B- and/or T-cell activation. Furthermore, while autoreactive cells in normal GCs undergo apoptosis before entering the follicle (peripheral check point), the same does not apply in the case of ectopic GCs or MZ equivalent in the salivary glands of SS patients, owing to deregulation of peripheral immune tolerance. Thus ectopic GCs and MZ in the salivary glands of SS patients harbor autoreactive cells [21]. AICDA expression has been reported to present in lymphoid MZ equivalents of salivary glands in SS patients in the absence of FDCs and B-T compartmentalization, the outcome of which leads to the abnormal activation of the molecular machinery that sustains *in situ* IgV repertoire diversification, isotype switching, B-cell differentiation, and oligoclonal expansion [19].

SS is characterized by the occurrence of high-affinity, class-switched autoantibodies, the presence of which represents a severe breakdown in B-cell tolerance [23]. Using the 9G4 anti-idiotypic mAb, which recognizes V4.34-encoded autoantibodies with autoreactivity against N-acetyllactosamine (NAL) determinants, it has been found that autoreactive B-cells bearing this idio type are preserved in real GCs and MZ equivalents in salivary glands of patients with SS [21]. These findings indicate that the tolerance check points that prohibit autoreactive B-cells from entering GCs or MZ could be defective in SS. Consequently, the microenvironment of ectopic lymphoid structures in SS represents a niche where autoreactive B-cells are abnormally activated and expanded via a T-cell dependent pathway in the presence of increased autoantigen expression [24,25].

The early accumulation of plasmacytoid dendritic cells (pDCs) in the target tissues, which produce high levels of type I interferons (IFNs), seems to be important for relaxation of the peripheral check point mechanism against autoreactivity during the transition from the new emigrant to mature naïve B-cells. In the presence of autoantibodies, pDCs can internalize RNA-containing autoantigen complexes from necrotic or apoptotic cells (via their Fc receptors) with subsequent stimulation of their Toll-like receptors (TLRs) in the endosomes. In turn, TLR ligation drives the production of IFN α , leading to the alteration of T-cell profiles, disruption of regulatory T-cell networks, alteration of B-cell development, and boosting of adaptive immunity [26]. When treated with IFN α , DCs mature, become more prone to activate T-cells and produce high levels of BAFF [27]. Additionally, BAFF can be also produced directly by salivary gland epithelium under the action of IFN α [28] as well as by B-cells themselves in an autocrine pattern of self-stimulation [29]. Thus, large quantities of BAFF can be produced in the SS lesion.

BAFF has a key role in SS-related B-cell deregulation, as it constitutes an essential factor of B-cell activation and proliferation. Under normal conditions, BAFF acts as a rheostat for B-cell selection such that increased competition among auto- and alloreactive B-cells for BAFF results in effective elimination of autoreactive B-cells [30]. Conversely, decreased competition for BAFF in the context of increased levels of circulating BAFF results in relaxation of BAFF selection and as a result the evasion of autoreactive naïve B-cells. Therefore, when BAFF is overexpressed, autoreactive B-cells survive and colonize follicles and MZ in extranodal sites [30]. BAFF actually, has been found to be increased in salivary glands of SS patients and these increased levels of BAFF, engaging the numerous receptors on salivary B-cells, have been implicated for the failure of the peripheral check point mechanism against autoreactivity and subsequent emergence of autoreactive B-cells in the GCs and MZ equivalents [31]. It should also be noted that the BAFF transgenic model of SS shares interesting features

with human disease such as B-cell hyperactivity, increased auto-antibody production, and salivary gland B-cell infiltrations with MZ B-cell phenotype [20,32,33]. Moreover, as in SS patients, BAFF transgenic mice also develop MZ B-cell lymphomas. Therefore, BAFF contributes not only to the development of autoimmune manifestations but may also be involved in B-cell malignancies observed in SS [20].

From a polyclonal process to lymphoma development

Transition from benign lymphoepithelial sialoadenitis (LESA) to NHL is thought to be a multi-stage and long-term process. Chronic antigenic stimulation plays a major role, both in the selection and expansion of B-cell clones, triggering the emergence of monoclonality which, combined with subsequent genetic disorders (i.e., chromosomal rearrangements, tumor-suppressing gene inactivation, and gene mutations leading to the dominance of the lymphocyte clone), results in neoplasia [14]. More specifically, increasing evidence suggests that mucosa-associated lymphoid tissue (MALT) lymphomas are related to chronic immune stimulation driven by bacterial, viral, or autoimmune stimuli. In the stomach, this has been linked to chronic gastritis in the presence of *Helicobacter pylori* infection [34]. Most patients (> 90%) with gastric MALT lymphoma are *H. pylori* positive. Cutaneous MALT lymphoma has been linked with *Borrelia burgdorferi* and *Borrelia afzelii* infection, the spirochetes responsible for Lyme disease in North America and Europe, respectively [35]. In the eyes, more than 80% of the cases of ocular adnexal lymphomas are related with *Chlamydia psittaci* infection [36]. Similarly, immunoproliferative small intestine disease (IPSID; also known as α -chain disease) is nowadays considered an extranodal MZ lymphoma associated with *Campylobacter jejuni* infection [37]. A major role of Hepatitis C (HCV) viral infection in pathogenesis of gastric MALT lymphomas has also been hypothesized [38]. Finally, similar chronic antigenic stimulation can be seen in autoimmune disorders, such as SS, relapsing polychondritis, and Hashimoto's thyroiditis, with or without coexisting infections [39,40]. It is unknown yet if an underlying infection actually triggers the lymphoma hyperplasia in these disorders.

Quite a number of patients with SS in the initial stage of the disease are characterized by the presence of monoclonal Igs and light-chains in the serum and urine, as well as by mixed monoclonal cryoglobulinemia (MMC) [41]. This suggests that in these patients, apart from polyclonal B-cell activation, there is also the presence of specific B-lymphocyte clones. We know today, through polymerase chain reaction (PCR), that in patients with SS it is possible to detect (at a rate > 50%) B-cell clonality in the salivary glands [42,43]. However, it should also be stressed that in individual patients, different B-cell clones may dominate at different time-points and in different tissues. This means that B-cell clonality is independent of lymphoma diagnosis.

Antigen selection of specific B-cells for transformation was suggested by a previous study on salivary gland mucosa-associated lymphoid tissue (MALT) lymphomas, in which three of five cases used the 51p1 VH and HumKv 325 VL genes that encodes the G6 and 17.109 idiotypes, respectively [44]. This implies that the clonal expansion in the salivary glands may arise from B-cells bearing Igs of a specific cross-reactive idio type. Furthermore, in the analysis of the IgVH gene of 11 distinct LESA-associated clones from sequential biopsies of different patients, eight were found to be derived from a V1-69 VH gene segment, whereas the remaining three originated from a V3-7 VH gene segment. The marked VH gene restriction, along with similar amino acid sequence motifs in the complementarity-determining region (CDR3), suggests that LESA-associated clones, even from

different patients, may bind the same or similar antigens and become selected by clonal expansion. In addition, the high rate of ongoing VH gene hypermutations in several cases and the low incidence of replacement mutations in the framework regions further indicate that the antigen receptor plays an important role in the development and expansion of LESA-associated clones [45]. It is highly likely that LESA-associated clones produce Igs with RF activity. This possibility is intimated by heavy- and light-chain CDR3 showing remarkable similarity to antibodies with RF activity and IgVH genes of LESA-associated clones sharing the same restriction repertoire with RF. The choice of specific segments, particularly the D21/9 segment, in the assembling of IgH chains seems to characterize a B-cell disorder with the capacity for the production of antibodies with RF activity [45]. A recent study suggests that salivary gland lymphoma in patients with SS frequently develops from RF-producing B-cells. A model for the increased frequency of lymphomas derived from specific RF B-cells in patients with SS could include the following: chronic stimulation by IgG or, more likely, by IgG complexed to auto- or exoantigens. It has been speculated that the substantial production of IgG in the salivary glands of patients with SS could lead to uncontrolled antigenic stimulation of RF B-cell clones in ectopic GCs where their vigorous expansion makes them prone to mutational events. These findings imply that surface Igs, both in benign lesions and in SS lymphoma infiltrates, exhibit RF-like activity [46]. Therefore, based on the above, we can conclude that SS is characterized by the expansion of monoclonal B-lymphocytes, in which surface Ig exhibits RF-like activity. It is these B-cells (and not the autoreactive B-cells producing anti-Ro and anti-La autoantibodies) that mediate lymphoma development. Notably, RF-bearing B-cells can internalize and present any autoantigen in the context of an immune complex. In turn, RF-positive B-cells can be stimulated by all local T helper cells that happen to have participated in helping make autoantibodies against these specific autoantigens and their individual epitopes [47]. By this way, a RF-positive B-cell receives a myriad of "hits" from many different local T helper cells. The nature of these expansions (whether small or large, localized or dispersed, or stable or intermittent) may be correlated with the risk of B-cell NHL [6].

As far as the molecular mechanism involved in lymphomagenesis is concerned, there seems to be involvement of dissimilar pathogenetic mechanisms in SS-related MALT lymphomas compared to MALT lymphomas in the general population. In contrast to other MALT lymphomas, where recurrent genetic abnormalities are reported, in SS such genetic aberrations have not yet been conclusively identified.

More specifically, the most commonly reported chromosomal abnormalities in MALT lymphomas include the following translocations: t(11;18) (q21;q21) (Apoptosis inhibitor-2 gene-*API-2*/MALT lymphoma-associated translocation protein-*MALT1*), t(14;18) (q32;q21) (*IgH/MALT1*), t(1;14) (p22;q32) (*BCL-10/IgH*), and t(3;14) (p13;q32) (*FOX-P1/IgH*). Apart from t(3;14), which results in an increase in nuclear levels of the *FOX-P1* transcription factor with its role remaining unknown, all other translocations lead to pathologic increase in the activation of the NF- κ B through the *BCL-10/MALT1* signaling complex thereby enhancing the survival of extranodal marginal zone cells. Activation of the NF- κ B pathway, which results in cell survival and proliferation, is an established and well-documented mechanism involved in lymphomagenesis. However, the translocations t(11;18) (q21;q21), t(14;18) (q32;q21), and t(1;14) (p22;q32) have been found in only relatively small proportions in SS MALT lymphoma patients [48]. Another possible genetic aberration correlating to MALT lymphomas is the deletion of the long arm of chromosome 6(6q23) leading to the deletion of TNF-induced protein 3 (A20). A20 is required for termination of TNF α and TLR-induced NF- κ B activation, thus the aforementioned genetic aberration leads to

increased signaling of NF- κ B pathway [49]. Clearly, a large cohort of SS lymphoma patients would be required to confirm A20 abolishment as a major molecular aberration in SS-associated NHLs.

Pathogenetically, lymphomagenesis in SS exhibits several similarities with lymphoma development in chronic HCV infection, sharing several characteristics such as MZ lymphoma predominance, mucosal involvement incidence, and a clear association with MMC. In this regard, a large percentage of HCV-associated NHLs originate from B-cell clones chronically stimulated by a common antigen. This is corroborated by the unique properties possessed by these B-cell clones; an R/S mutation ratio in the framework segments of Ig lower than that expected by chance and a highly restricted use of gene segments in assembling the IgH chain [50]. Furthermore, the significant homologies between gene segments used by these lymphoma cells and those used by antibodies with RF activity suggest that these NHLs are derived from B-cell clones that produce RF [51]. Given that these genes have been associated with the cross-reactive idiotypes expressed by serum monoclonal components in type II cryoglobulinemia, it is plausible that HCV-associated NHLs originate from the neoplastic transformation of the same clones expanded in type II cryoglobulinemia. It has been postulated that HCV, as an exogenous antigen in complex with IgG, triggers distinct RF B-cell clones. Furthermore, the preferential usage of a V1-69 VH in combination with the HumKv 325 VL gene, the use of specific segments, in assembling the IgH chain of Ig, in particular the D21/9 segment, and the restricted length of CDR3 region, all indicate that HCV-associated neoplasms are closely related to salivary gland MALT lymphomas in terms of pathogenesis [52,53]. Just as IgG-bound viral protein immune complexes drive the expansion of RF B-cells in HCV infection, so IgG-bound chromatin and anti-Ro-ribonucleoprotein immune complexes prompt a similar activity in SS patients. It has been proposed that RF B-cells in SS are expanded in response to dual ligation of BCRs and TLRs by immune complexes containing RNA/DNA. Therefore the combined signals of BCR, TLR, and BAFF create a loop that propagates the production of autoantibodies and leads to expansion of RF B-cells [30]. Interestingly, although 40% of the salivary MALT lymphomas express RF BCR, this specificity of BCR does not characterize MALT lymphomas with t(11;18) chromosomal translocation. This inverse relation between RF-specificity and the t(11;18) suggests that expansion of MALT lymphomas containing t(11;18) is not dependent on BCR, TLR, or CD40-mediated NF- κ B activation [7]. On the other hand, t(11;18)-negative salivary gland MALT lymphomas with RF BCR may need chronic stimulation by IgG in immune complexes. Therefore, their proliferation depends on activated NF- κ B signaling, which is provoked by combined signals resulting from CD40/BCR/TLR stimulation [17] (Fig. 2).

It is feasible that the microenvironment of ectopic GCs in the salivary glands of patients with SS, in which B-cell lymphocytes undergo intense proliferation, may impede variable region gene recombination, thereby inactivating tumor suppression genes or activating proto-oncogenes. Abnormalities in the control of the V(D)J recombination process could play a significant role in neoplastic transformation in 60% of SS patients lacking RF B-cell receptors [54]. Sequence analysis of the P53 gene in five patients with SS with MALT lymphomas revealed two novel mutations of exon 5. These mutations are single-base substitutions and appear functional, since exon 5 is included in the coding region of the p53 gene [55]. Mutant p53 proteins without tumor suppressor activity could well lead to checkpoint failure at the cell cycle level, followed by uncontrolled cell proliferation. This finding implies the probable role of this tumor suppressor gene as a potential mechanism for lymphoma development in SS.

Benign chronic LESA and MALT lymphoma can further undergo transition to high-grade lymphoma, e.g., diffuse large B-cell

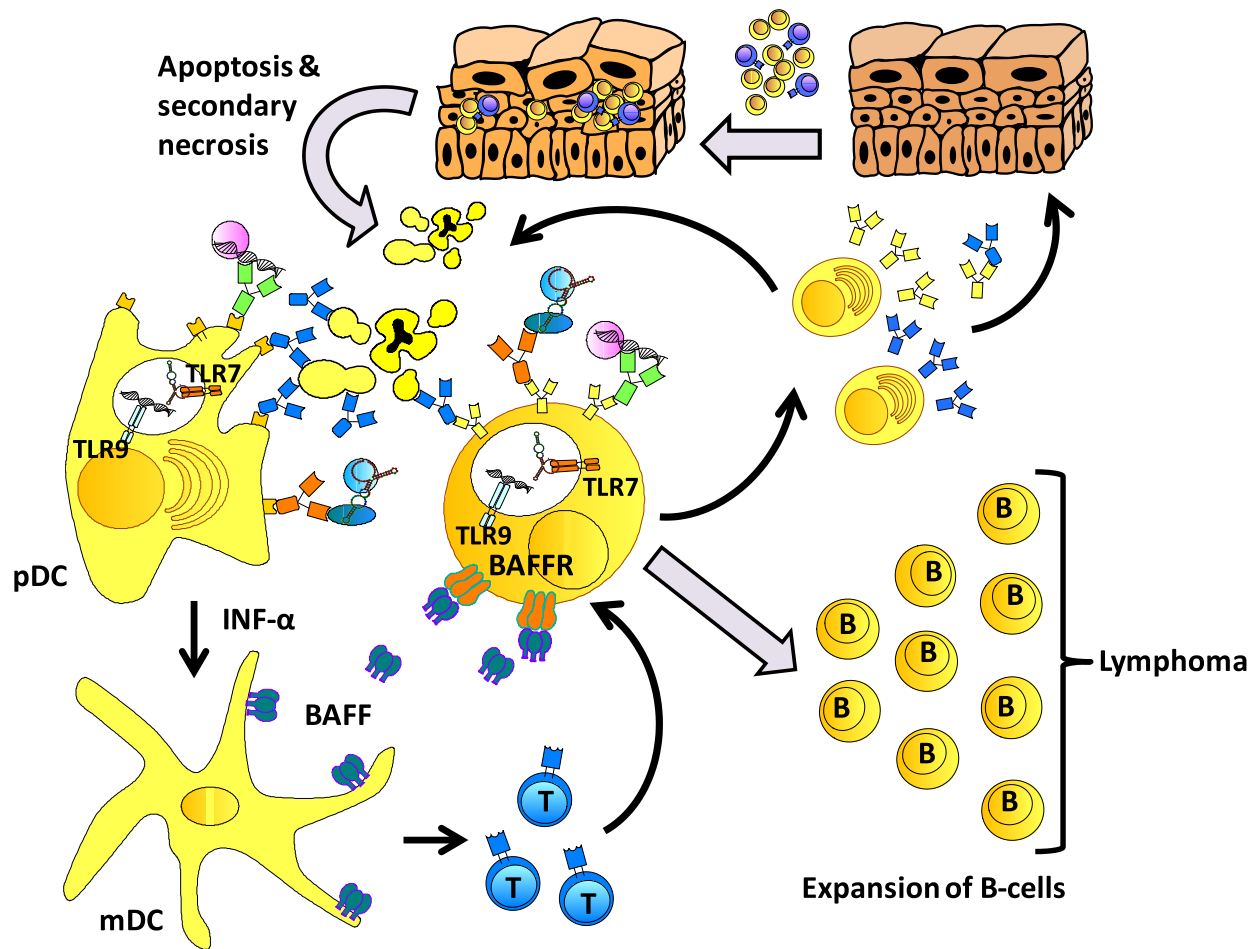


Fig. 2. Cellular and molecular pathways implicated in lymphomagenesis in Sjögren's syndrome: Environmental factors (e.g., viral infection) and hormonal factors, in concert with an appropriate genetic background, are believed to deregulate salivary gland epithelial cells and allow the aberrant homing of autoreactive B- and T-cells. Following the migration of lymphocytes into the glands, epithelial cells are further activated by proinflammatory cytokines (IL-1 β , IFN- γ and TNF), which are produced by adjacent T-cells. Consequently, tissue damage occurs due to immune attack mediated by a combination of apoptosis and cytotoxic cell death [29], which is followed by secondary necrosis and release of autoantigens. Alternatively, activated non-apoptotic epithelium releases exosomes containing intracellular autoantigenic complexes [15]. In both cases, the nucleic acid-containing autoantigenic complexes acting through TLRs activate plasmacytoid DCs. The early accumulation of pDCs in the target tissues, which produce high levels of type I IFNs, seems to be important, as these cells can further deregulate the immune response through abnormal retention of lymphocytes in the tissues and their subsequent activation. IFN- α is a powerful stimulator of the production of BAFF by mDCs. Abundant BAFF production stimulates aberrant B-cell maturation, leading to the emergence of self-reactive B-cells, which locally produce autoantibodies and rheumatoid factors. Sustained survival of autoreactive B-cells leads to the sustained production of autoantibodies and in some cases to the expansion of clones with surface immunoglobulins that exhibit RF-like activity, which are implicated for lymphoma development. Abbreviations: BAFF, B-cell activating factor; BAFFR, BAFF receptor; pDCs, plasmacytoid dendritic cells; mDCs, myeloid dendritic cells; IFN- α , interferon- α .

lymphoma (DLBCL), represents a multistep process involving genetic alterations such as p53 allelic loss and mutations, hypermethylation of p15 and p16 genes, and p16 gene deletions [56,57]. The transformation of MALT lymphoma to DLBCL is heralded by the emergence of an increased number of transformed blasts that form clusters to finally form a confluence effacing the preceding MALT lymphoma. It is unclear how many DLBCLs arise from pre-existing MALT, nodal, or follicular lymphomas. Immuno-histochemical, karyotypic, and genotypic studies have provided convincing proof that the supervening large-cell lymphomas arise from the same clone as the low-grade lymphomas [56]. Thus, the majority of high-grade lymphomas in SS patients may represent blastic-variance of either MZ B-cell or follicular center cell lymphomas.

Prognostic risk factors for lymphoma

Identification of specific parameters in high-risk patients for B-cell NHL in SS is necessary for the proper monitoring of these patients. All studies have identified parameters that fit the aforementioned model: the gradual expansion of B-cell clones with

surface Igs exhibiting RF-like activity. Subsequently, these clones may induce MMC and low serum C4, with intercurrent clinical manifestations such as severe involvement of the exocrine glands, peripheral neuropathy, and purpura [58,59]. In 1971, Anderson et al. [60] demonstrated that a decrease in serum Ig levels and disappearance of the RF constitute a hallmark of progression to lymphoma; while in 1978, Kassan et al. [61] showed that SS patients who presented clinical parameters such as lymphadenopathy, splenomegaly, and parotid enlargement experienced an increased risk of lymphoma development. Skopouli et al. [6] have determined that low C4 in combination with MMC is a risk factor for NHL in patients with SS. In another study, Ioannidis et al. [5] have certified that parotid gland enlargement, palpable purpura, and low C4 are independent risk factors for NHL and have classified patients with SS into two groups. The first group includes patients who have these parameters, are classified as high-risk, and need closest monitoring compared to the second group consisting of low-risk patients who do not have these parameters.

Given the risk factors for lymphomagenesis in the setting of SS, patients can be classed as high- or low-risk, and follow-up managed accordingly. Hence, for patients without risk factors,

basic laboratory evaluation with CBC and biochemistry profile and complete physical examination constitute the gold standard for routine annual follow-up. In contrast, patients with risk factors for lymphoma development, i.e., patients expressing clinical characteristics such as purpura, salivary gland enlargement, or lymphadenopathy should undergo routine 6-monthly follow-up in addition to a complete physical examination that should always include complete blood count (CBC), biochemistry panel, serum protein electrophoresis, serum and urine immunofixation, serum cryoglobulins, serum complement levels, and RF activity.

The association between low C4 levels and lymphoma in SS patients was also demonstrated strongly in a univariate analysis by Ramos-Casal, where low C4 levels constituted an independent variable in a multivariate analysis [62]. It should also be noted that in another model, CD4 T-lymphocytopenia was also identified as a risk factor for lymphoma, associating therefore immunodeficiency with lymphomagenesis in SS [63].

Other reports evaluating associations between biological and clinical parameters and lymphoma risk in SS patients identified increased levels of β -2 microglobulin, and low serum levels of IgM, as well as vasculitic ulcers and immunosuppressive treatment, as possible predictors of lymphoma development [64–66]. Today, it is commonly accepted that the presence of cryoglobulinemia, low C4, splenomegaly, lymphadenopathy, and neutropenia are independent risk factors for NHL. The presence of even one of these parameters increases the lymphoma risk fivefold [67].

It has become clear that lymphoma in SS is a late process in the course of the syndrome. A multicenter trial has found that the median time to lymphoma occurrence since SS diagnosis is 7.5 years, while its incidence in patients with SS is 4.3% [68].

There is conflicting evidence in the literature concerning the exact rate of lymphomas developing in patients with SS; the difference ranges between 5% and 10% and depends on the total number of patients and the follow-up time of each study [14]. We already know that the further we move away from the time of SS diagnosis, the higher the risk of NHL. We have observed that 10–15 years after diagnosis, the relative danger is 20 times higher than in the general population [69].

In a single-center retrospective study evaluating lymphoma development in a cohort of 584 SS patients over a 30-year follow-up period, it was established that the longer the follow-up time, the higher the recorded incidence of lymphoma. Over a 30-year period, the recorded incidence of lymphoma reached 9% [69].

These patients are characterized by a particular clinical picture, absent in other lymphomas or in patients without lymphoma. They mainly manifest skin vasculitis and peripheral neuropathy, while the main findings of the laboratory tests are anemia, lymphocytopenia, hypergammaglobulinemia, paraproteinemia, and MMC [68]. Furthermore, lymphocytopenia, low CD4, cryoglobulinemia, and purpura are characteristic parameters in these patients, while they are not particularly common in patients who do not develop lymphoma.

Types of lymphoma in Sjögren's syndrome

There are two dominant types of lymphoma in SS:

1. The first type includes MZ lymphomas classified as:
 - extranodal MZ lymphomas (called MALT lymphomas) and
 - nodal MZ lymphomas.
2. The second type consists of aggressive lymphomas such as DLBCL.

MALT lymphomas (Fig. 3) mainly involve extranodal sites. On the other hand, nodal MZ lymphomas show an entirely different

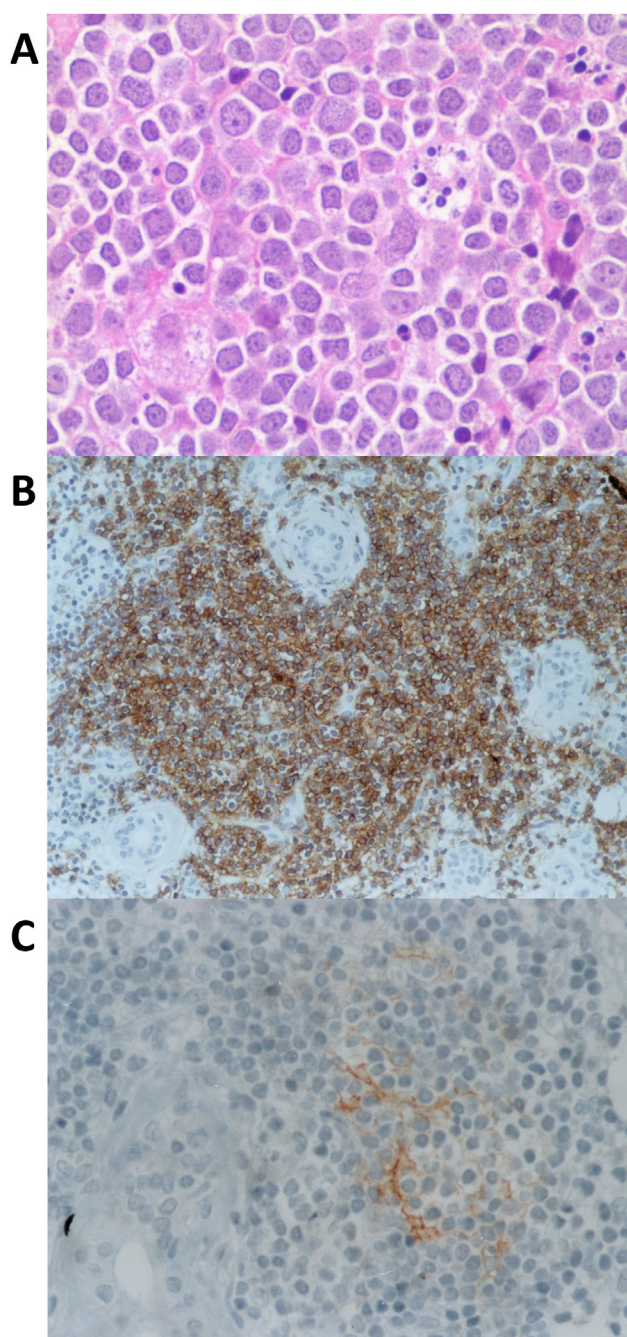


Fig. 3. MALT lymphomas: (A) infiltration by small lymphocytes and plasma cells (H & E, $\times 400$); (B) atypical lymphocytes diffusely positive for CD20 (immunostaining with L26 antibody, $\times 100$); and (C) immunostaining with anti-CD21 ($\times 200$) for follicular dendritic cells. Immunohistology data, together with the histological findings, suggest the existence of a B-cell lymphoma in salivary glands.

clinical picture, which, in the advanced stage, is characterized by bone marrow infiltration, lymphadenopathy, and the absence of extranodal foci involvement [70]. Of note, 10% of MALT lymphomas convert to high-grade malignant lymphomas. MALT lymphomas are benign, characterized by clusters of centrocytes, monocyte-like cells, and immunoblasts with specific morphological features: they are surrounding the GCs, infiltrate the epithelium, and form lymphoepithelial lesions. Typically, MALT lymphomas are localized, with no BM involvement, no splenomegaly, and no B symptoms. The main extranodal involvement sites are the salivary glands; however in 20% of the patients we may observe

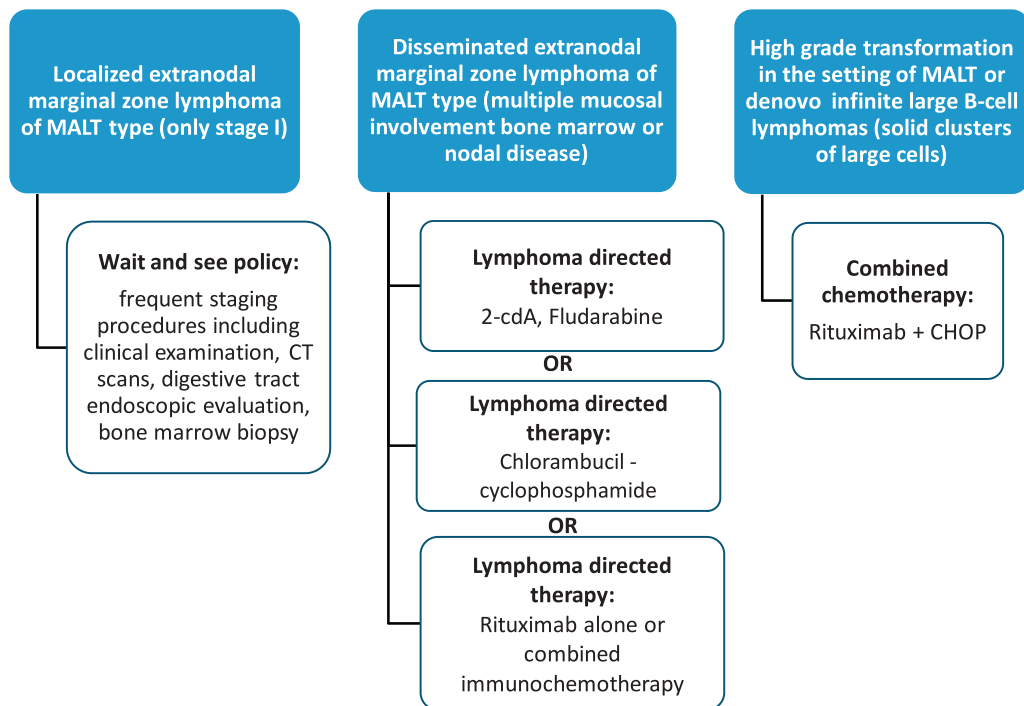


Fig. 4. Algorithm for the therapeutical approach of lymphoma in patients with SS [77–82].

involvement of more than one extranodal site and therefore extensive clinical-laboratory assessment is required for diagnosis and staging. Regardless of the presentation site, diagnostic studies should always include the standard lymphoma staging procedures and in addition the examination of Waldeyer's ring. Once the diagnosis of MALT lymphoma is established, a radiographic examination with CT scans of the neck, chest, abdomen, and pelvis should follow. Laboratory evaluation should also include a CBC count, chemistry panel, MMC, LDH level, and serum protein electrophoresis. Furthermore, BM aspiration and biopsy are necessary to assess possible dissemination to the marrow. The initial staging should include a gastroduodenal endoscopy with multiple blind biopsies as well as biopsies from any site that appears macroscopically abnormal. A possible *H. pylori* infection also needs to be excluded. Special diagnostic procedures may prove necessary. In this regard, pulmonary opacities should be assessed histologically for the exclusion of bronchial MALT lymphoma. An endoscopic ultrasound is strongly recommended in the case of gastric involvement.

Prognosis and treatment

In general, prognosis in MALT lymphomas is very good, and the 5-year survival reaches 90%. In patients with MALT lymphomas, in non-SS population, there are certain parameters that determine a poorer prognosis [71]. Although involvement of other extranodal sites does not influence the prognosis, in patients with poorer prognosis, BM infiltration and lymphadenopathy are detected. Furthermore, the International Prognostic Index (IPI) score based on five parameters (age, stage, involvement of many extranodal sites, performance status, and LDH), prognostically distinguishes the patients with MALT lymphoma [72,73]. Specifically, when these parameters are added up, patients have poorer prognosis compared to those that have none of these parameters. Survival of the latter is very good, almost the same as in the general population.

There is no therapeutic algorithm for MZ lymphomas in SS, nevertheless, two large studies exist that evaluate SS-related lymphoma development and management. Both studies reach similar conclusions. Pollard et al. [74] studied 35 MALT-lymphoma SS patients in a cohort of 329 SS patients with localized disease in the parotids. They conclude that patients with high SS disease activity (M-protein, cryoglobulins, IgM RF > 100 kIU/L, and severe extraglandular manifestations) with or without MALT lymphoma may require treatment; while in SS patients with localized MALT and low disease activity, a watchful-waiting strategy is justified. On the other hand, Voulgarelis et al. [69] studied 53 consecutive NHL cases in a cohort of 584 SS patients over a 30-year study period. In this study MALT lymphomas (localized or not) constituted the majority of NHL subtypes followed by nodal MZ lymphomas and DLBCL. Based on the tactics used in the therapeutic management of SS-related lymphoma in this study, the authors propose the following strategies (Fig. 4).

In asymptomatic, localized MALT lymphomas, without BM involvement and lymphadenopathy, with IPI score between 0 and 1, the patient is under close follow-up with no therapeutic intervention. Usually, over a median follow-up time of 4 years, these patients do not develop disease progression or transition to high-grade malignant lymphoma. The only exception is the presence of extranodal manifestations, such as cryoglobulinemia, where treatment with Rituximab is indicated.

In disseminated MALT lymphoma with high IPI score and BM and lymph-node involvement, Rituximab is administered concomitantly with chemotherapy. This treatment schedule has been used in 31 MALT lymphomas. It accounts the most adequate therapeutic algorithm for the treatment of MALT lymphomas; its use in these patients has led to a 3-year overall survival of 97% and a 3-year disease-free survival of 80%.

In nodal lymphomas, on the contrary, results have not been encouraging as 3-year overall survival was approximately 80% and 3-year event-free survival was lower than 50%, which shows that these lymphomas have a completely different pathogenicity and that they should be investigated in a different way and may necessitate new therapeutic approaches [69].

Regarding DLBC lymphoma, the addition of Rituximab to the traditional CHOP chemotherapy has resulted in increasing the 2-year overall survival from 37% to 100% [69,75]. As a conclusion, the combination of Rituximab-CHOP is the standard of care for these lymphomas, as until now we have achieved 100% overall survival and 100% event-free survival after 3 years [69]. Furthermore, this combination achieves control of extranodal manifestations, with a decrease in cryoglobulin levels, an increase in C4 levels, and a decrease in RF levels, without any particular adverse events [69].

At this point it should be stressed that lymphoma is the main cause of death in patients with SS and that the standardized mortality ratio is 3.25 in SS patients with lymphoma and 1.08 in SS patients without lymphoma (almost the same as in the general population), while, on the basis of statistical data, lymphoma in SS is responsible for 1.58 deaths per 1000 patient-years [69].

References

- [1] Soliotis FC, Moutsopoulos HM. Sjogren's syndrome. *Autoimmunity* 2004; 37(4):305-7.
- [2] Smedby KE, Hjalgrim H, Askling J, Chang ET, Gregersen H, Porwit-MacDonald A, et al. Autoimmune and chronic inflammatory disorders and risk of non-Hodgkin lymphoma by subtype. *J Nat Cancer Inst* 2006;98(1):51-60.
- [3] Zintzaras E, Voulgarelis M, Moutsopoulos HM. The risk of lymphoma development in autoimmune diseases: a meta-analysis. *Arch Intern Med* 2005;165(20):2337-44.
- [4] Voulgarelis M, Moutsopoulos HM. Lymphoproliferation in autoimmunity and Sjogren's syndrome. *Curr Rheumatol Rep* 2003;5(4):317-23.
- [5] Ioannidis JPA, Vassiliou VA, Moutsopoulos HM. Long-term risk of mortality and lymphoproliferative disease and predictive classification of primary Sjogren's syndrome. *Arthritis Rheum* 2002;46(3):741-7.
- [6] Skopouli FN, Dafni U, Ioannidis JPA, Moutsopoulos HM. Clinical evolution, and morbidity and mortality of primary Sjogren's syndrome. *Semin Arthritis Rheum* 2000;29(5):296-304.
- [7] Bende RJ, van Maldeghem F, van Noesel CJ. Chronic inflammatory disease, lymphoid tissue neogenesis and extranodal marginal zone B-cell lymphomas. *Haematologica* 2009;94(8):1109-23.
- [8] Lesley R, Xu Y, Kalled LM, Hess DM, Schwab SR, Shu HB, et al. Reduced competitiveness of autoantigen-engaged B cells due to increased dependence on BAFF. *Immunity* 2004;20(4):441-53.
- [9] Martin F, Kearney JF. Marginal-zone B cells. *Nat Rev Immunol* 2002;2(5):323-335.
- [10] Saito T, Chiba S, Ichikawa M, Kunisato A, Asai T, Shimizu K, et al. Notch2 is preferentially expressed in mature B cells and indispensable for marginal zone B lineage development. *Immunity* 2003;18(5):675-85.
- [11] Dunn-Walters DK, Isaacson PG, Spencer J. Analysis of mutations in immunoglobulin heavy chain variable region genes of microdissected marginal zone (MGZ) B cells suggests that the MGZ of human spleen is a reservoir of memory B cells. *J Exp Med* 1995;182(2):559-66.
- [12] Tsuji M, Yurasov S, Velinzon K, Thomas S, Nussenzweig MC, Wardemann H. A checkpoint for autoreactivity in human IgM+ memory B cell development. *J Exp Med* 2006;203(2):393-400.
- [13] Routsias JG, Tzioufas AG. Autoimmune response and target autoantigens in Sjogren's syndrome. *Eur J Clin Invest* 2010;40(11):1026-36.
- [14] Tzioufas AG, Voulgarelis M. Update on Sjogren's syndrome autoimmune epithelitis: from classification to increased neoplasias. *Best Pract Res Clin Rheumatol* 2007;21(6):989-1010.
- [15] Mitsias DI, Kapsogeorgou EK, Moutsopoulos HM. The role of epithelial cells in the initiation and perpetuation of autoimmune lesions: lessons from Sjogren's syndrome (autoimmune epithelitis). *Lupus* 2006;15(5):255-61.
- [16] Dimitriou ID, Kapsogeorgou EK, Moutsopoulos HM, Manoussakis MN. CD40 on salivary gland epithelial cells: high constitutive expression by cultured cells from Sjogren's syndrome patients indicating their intrinsic activation. *Clin Exp Immunol* 2002;127(2):386-92.
- [17] Daridon C, Pers JO, Devauchelle V, Martins-Carvalho C, Hutin P, Pennec YL, et al. Identification of transitional type II B cells in the salivary glands of patients with Sjogren's syndrome. *Arthritis Rheum* 2006;54(7):2280-8.
- [18] Theander E, Vasaitis L, Baecklund E, Nordmark G, Warfvinge G, Liedholm R, et al. Lymphoid organisation in labial salivary gland biopsies is a possible predictor for the development of malignant lymphoma in primary Sjogren's syndrome. *Ann Rheum Dis* 2011;70(8):1363-8.
- [19] Bombardieri M, Barone F, Humby F, Kelly S, McGurk M, Morgan P, et al. Activation-induced cytidine deaminase expression in follicular dendritic cell networks and interfollicular large B cells supports functionality of ectopic lymphoid neogenesis in autoimmune sialadenitis and MALT lymphoma in Sjogren's syndrome. *J Immunol* 2007;179(7):4929-38.
- [20] Mackay F, Groom JR, Tangye SG. An important role for B-cell activation factor and B cells in the pathogenesis of Sjogren's syndrome. *Curr Opin Rheumatol* 2007;19(5):406-13.
- [21] Le Pottier L, Devauchelle V, Fautrel A, Daridon C, Saraux A, Youinou P, et al. Ectopic germinal centers are rare in Sjogren's syndrome salivary glands and do not exclude autoreactive B cells. *J Immunol* 2009;182(6):3540-7.
- [22] Aloisi F, Pujol-Borrell R. Lymphoid neogenesis in chronic inflammatory diseases. *Nat Rev Immunol* 2006;6(3):205-17.
- [23] Fauchais AL, Martel C, Gondran G, Lambert M, Launay D, Jauberteau MO, et al. Immunological profile in primary Sjogren syndrome: clinical significance, prognosis and long-term evolution to other auto-immune disease. *Autoimmun Rev* 2010;9(9):595-9.
- [24] Barcellos KS, Nonogaki S, Enokihara MM, Teixeira MS, Andrade LE. Differential expression of Ro/SSA 60 kDa and La/SSB, but not Ro/SSA 52 kDa, mRNA and protein in minor salivary glands from patients with primary Sjogren's syndrome. *J Rheumatol* 2007;34(6):1283-92.
- [25] de Wilde PC, Kater L, Bodeutsch C, van den Hoogen FH, van de Putte LB, van Venrooij WJ. Aberrant expression pattern of the SS-B/La antigen in the labial salivary glands of patients with Sjogren's syndrome. *Arthritis Rheum* 1996;39(5):783-91.
- [26] Niewold TB, Clark DN, Salloum R, Poole BD. Interferon alpha in systemic lupus erythematosus. *J Biomed Biotechnol* 2010;2010:948364.
- [27] Farkas A, Tonel G, Nestle FO. Interferon-alpha and viral triggers promote functional maturation of human monocyte-derived dendritic cells. *Br J Dermatol* 2008;158(5):921-9.
- [28] Lavie F, Miceli-Richard C, Ittah M, Sellam J, Gottenberg JE, Mariette X. B-cell activating factor of the tumour necrosis factor family expression in blood monocytes and T cells from patients with primary Sjogren's syndrome. *Scand J Immunol* 2008;67(2):185-92.
- [29] Daridon C, Devauchelle V, Hutin P, Le Berre R, Martins-Carvalho C, Bendaoud B, et al. Aberrant expression of BAFF by B lymphocytes infiltrating the salivary glands of patients with primary Sjogren's syndrome. *Arthritis Rheum* 2007; 56(4):1134-44.
- [30] Moisini I, Davidson A. BAFF: a local and systemic target in autoimmune diseases. *Clin Exp Immunol* 2009;158(2):155-63.
- [31] Varin MM, Le Pottier L, Youinou P, Saulep D, Mackay F, Pers JO. B-cell tolerance breakdown in Sjogren's syndrome: focus on BAFF. *Autoimmun Rev* 2010; 9(9):604-8.
- [32] Batten M, Groom J, Cachero TG, Qian F, Schneider P, Tschopp J, et al. BAFF mediates survival of peripheral immature B lymphocytes. *J Exp Med* 2000; 192(10):1453-66.
- [33] Batten M, Fletcher C, Ng LG, Groom J, Whewey J, Laabi Y, et al. TNF deficiency fails to protect BAFF transgenic mice against autoimmunity and reveals a predisposition to B cell lymphoma. *J Immunol* 2004;172(2):812-22.
- [34] Wotherspoon AC. Gastric MALT lymphoma and *Helicobacter pylori*. *Yale J Biol Med* 1996;69(1):61-8.
- [35] Schollkopf C, Melbye M, Munksgaard L, Smedby KE, Rostgaard K, Glimelius B, et al. Borrelia infection and risk of non-Hodgkin lymphoma. *Blood* 2008; 111(12):5524-9.
- [36] Ponzoni M, Ferreri AJ, Guidoboni M, Lettini AA, Cangini MG, Pasini E, et al. Chlamydia infection and lymphomas: association beyond ocular adnexal lymphomas highlighted by multiple detection methods. *Clin Cancer Res* 2008;14(18):5794-800.
- [37] Lecuit M, Abachin E, Martin A, Poyart C, Pochart P, Suarez F, et al. Immuno-proliferative small intestinal disease associated with *Campylobacter jejuni*. *N Engl J Med* 2004;350(3):239-48.
- [38] Luppi M, Longo G, Ferrari MG, Ferrara L, Marasca R, Barozzi P, et al. Prevalence of HCV infection and second neoplasms in marginal zone lymphomas. *British J Haematol* 1997;96(4):873-4.
- [39] Ramos-Casals M, la Civita L, de Vita S, Solans R, Luppi M, Medina F, et al. Characterization of B cell lymphoma in patients with Sjogren's syndrome and hepatitis C virus infection. *Arthritis and rheumatism* 2007;57(1):161-70.
- [40] Zucca E, Bertoni F, Roggero E, Cavalli F. The gastric marginal zone B-cell lymphoma of MALT type. *Blood* 2000;96(2):410-9.
- [41] Manthorpe R, Bredberg A, Henriksson G, Larsson A. Progress and regression within primary Sjogren's syndrome. *Scand J Rheumatol* 2006;35(1):1-6.
- [42] Guzman LM, Castillo D, Aguilera SO. Polymerase chain reaction (PCR) detection of B cell clonality in Sjogren's syndrome patients: a diagnostic tool of clonal expansion. *Clin Exp Immunol* 2011;161(1):57-64.
- [43] Tokuno T, Takahashi H, Suzuki C, Yamamoto M, Naishiro Y, Sugaya A, et al. Analysis of B-cell clonality in the hepatic tissue of patients with Sjogren's syndrome. *Scand J Rheumatol* 2003;32(5):268-72.
- [44] Bahler DW, Miklos JA, Swerdlow SH. Ongoing Ig gene hypermutation in salivary gland mucosa-associated lymphoid tissue-type lymphomas. *Blood* 1997;89(9):3335-44.
- [45] Bahler DW, Swerdlow SH. Clonal salivary gland infiltrates associated with myoepithelial sialadenitis (Sjogren's syndrome) begin as nonmalignant antigen-selected expansions. *Blood* 1998;91(6):1864-72.
- [46] Martin T, Weber JC, Levallois H, Labouret N, Soley A, Koenig S, et al. Salivary gland lymphomas in patients with Sjogren's syndrome may frequently develop from rheumatoid factor B cells. *Arthritis Rheum* 2000;43(4):908-16.
- [47] Roosnek E, Lanzavecchia A. Efficient and selective presentation of antigen-antibody complexes by rheumatoid factor B cells. *J Exp Med* 1991; 173(2):487-9.
- [48] Joao C, Farinha P, da Silva MG, Martins C, Crespo M, Cabecadas J. Cytogenetic abnormalities in MALT lymphomas and their precursor lesions from different organs. A fluorescence in situ hybridization (FISH) study. *Histopathology* 2007;50(2):217-24.

- [49] Chanudet E, Ye H, Ferry J, Bacon CM, Adam P, Muller-Hermelink HK, et al. A20 deletion is associated with copy number gain at the TNFA/B/C locus and occurs preferentially in translocation-negative MALT lymphoma of the ocular adnexa and salivary glands. *J Pathol* 2009;217(3):420–30.
- [50] Ivanovski M, Silvestri F, Pozzato G, Anand S, Mazzaro C, Burrone OR, et al. Somatic hypermutation, clonal diversity, and preferential expression of the VH 51p1/VL kv325 immunoglobulin gene combination in hepatitis C virus-associated immunocytomas. *Blood* 1998;91(7):2433–42.
- [51] Dammacco F, Sansonno D, Piccoli C, Racanelli V, D'Amore FP, Lauletta G. The lymphoid system in hepatitis C virus infection: autoimmunity, mixed cryoglobulinemia, and Overt B-cell malignancy. *Semin Liver Dis* 2000;20(2):143–57.
- [52] De ReV, De Vita S, Marzotto A, Rupolo M, Ghoghini A, Pivetta B, et al. Sequence analysis of the immunoglobulin antigen receptor of hepatitis C virus-associated non-Hodgkin lymphomas suggests that the malignant cells are derived from the rheumatoid factor-producing cells that occur mainly in type II cryoglobulinemia. *Blood* 2000;96(10):3578–84.
- [53] Miklos JA, Swerdlow SH, Bahler DW. Salivary gland mucosa-associated lymphoid tissue lymphoma immunoglobulin V(H) genes show frequent use of V1-69 with distinctive CDR3 features. *Blood* 2000;95(12):3878–84.
- [54] Kuppers R, Klein U, Hansmann ML, Rajewsky K. Cellular origin of human B-cell lymphomas. *N Engl J Med* 1999;341(20):1520–9.
- [55] Tapinos NI, Polihronis M, Moutsopoulos HM. Lymphoma development in Sjogren's syndrome: novel p53 mutations. *Arthritis Rheum* 1999;42(7):1466–1472.
- [56] Rossi D, Gaidano G. Molecular heterogeneity of diffuse large B-cell lymphoma: implications for disease management and prognosis. *Hematology* 2002;7(4):239–252.
- [57] Neumeister P, Hoefler G, Beham-Schmid C, Schmidt H, Apfelbeck U, Schaidler H, et al. Deletion analysis of the p16 tumor suppressor gene in gastrointestinal mucosa-associated lymphoid tissue lymphomas. *Gastroenterology* 1997;112(6):1871–5.
- [58] Tzioufas AG, Boumba DS, Skopouli FN, Moutsopoulos HM. Mixed monoclonal cryoglobulinemia and monoclonal rheumatoid factor cross-reactive idiotypes as predictive factors for the development of lymphoma in primary Sjogren's syndrome. *Arthritis Rheum* 1996;39(5):767–72.
- [59] Voulgarelis M, Tzioufas AG. Pathogenetic mechanisms in the initiation and perpetuation of Sjogren's syndrome. *Nat Rev Rheumatol* 2010;6(9):529–37.
- [60] Anderson LG, Talal N. The spectrum of benign to malignant lymphoproliferation in Sjogren's syndrome. *Clin Exp Immunol* 1972;10(2):199–221.
- [61] Kassan SS, Thomas TL, Moutsopoulos HM, Hoover R, Kimberly RP, Budman DR, et al. Increased risk of lymphoma in sicca syndrome. *Ann Intern Med* 1978;89(6):888–92.
- [62] Ramos-Casals M, Brito-Zeron P, Yague J, Akasbi M, Bautista R, Ruano M, et al. Hypocomplementaemia as an immunological marker of morbidity and mortality in patients with primary Sjogren's syndrome. *Rheumatology* 2005;44(1):89–94.
- [63] Theander E, Henriksson G, Ljungberg O, Mandl T, Manthorpe R, Jacobsson LTH. Lymphoma and other malignancies in primary Sjogren's syndrome: a cohort study on cancer incidence and lymphoma predictors. *Ann Rheum Dis* 2006;65(6):796–803.
- [64] Anaya JM, McGuff HS, Banks PM, Talal N. Clinicopathological factors relating malignant lymphoma with Sjogren's syndrome. *Semin Arthritis Rheum* 1996;25(5):337–46.
- [65] Sutcliffe N, Inanc M, Speight P, Isenberg D. Predictors of lymphoma development in primary Sjogren's syndrome. *Semin Arthritis Rheum* 1998;28(2):80–87.
- [66] Leandro MJ, Isenberg DA. Rheumatic diseases and malignancy—is there an association? *Scand J Rheumatol* 2001;30(4):185–8.
- [67] Voulgarelis M, Moutsopoulos HM. Malignant lymphoma in primary Sjogren's syndrome. *Israel Med Assoc J* 2001;3(10):761–6.
- [68] Voulgarelis M, Dafni UG, Isenberg DA, Moutsopoulos HM. Malignant lymphoma in primary Sjogren's syndrome: a multicenter, retrospective, clinical study by the European concerted action on Sjogren's syndrome. *Arthritis Rheum* 1999;42(8):1765–72.
- [69] Voulgarelis M, Ziakas PD, Papageorgiou A, Baimpa E, Tzioufas AG, Moutsopoulos HM. Prognosis and outcome of non-Hodgkin lymphoma in primary Sjogren syndrome. *Medicine* 2012;91(1):1–9.
- [70] Inamdar KV, Medeiros LJ, Jorgensen JL, Amin HM, Schlette EJ. Bone marrow involvement by marginal zone B-cell lymphomas of different types. *Am J Clin Pathol* 2008;129(5):714–22.
- [71] Voulgarelis M, Moutsopoulos HM. Mucosa-associated lymphoid tissue lymphoma in Sjogren's syndrome: risks, management, and prognosis. *Rheum Dis Clin North Am* 2008;34(4):921–33 [viii].
- [72] Castrillo JM, Montalban C, Abaira V, Carrion R, Cruz MA, Larana JG, et al. Evaluation of the international index in the prognosis of high grade gastric malt lymphoma. *Leuk Lymphoma* 1996;24(1–2):159–63.
- [73] Gill H, Chim CS, Au WY, Loong F, Tse E, Leung AY, et al. Non-gastric marginal zone B cell lymphoma: clinicopathologic features and treatment results. *Ann Hematol* 2011.
- [74] Pollard RP, Pijpe J, Bootsma H, Spijkervet FK, Kluin PM, Roodenburg JL, et al. Treatment of mucosa-associated lymphoid tissue lymphoma in Sjogren's syndrome: a retrospective clinical study. *J Rheumatol* 2011;38(10):2198–208.
- [75] Saraux A. The point on the ongoing B-cell depleting trials currently in progress over the world in primary Sjogren's syndrome. *Autoimmun Rev* 2010;9(9):609–614.
- [76] Christodoulou MI, Kapsogeorgou EK, Moutsopoulos HM. Characteristics of the minor salivary gland infiltrates in Sjogren's syndrome. *J Autoimmun* 2010;34(4):400–7.
- [77] Conconi A, Martinelli G, Thiéblemont C, Ferreri AJM, Devizzi L, Peccatori F, et al. Clinical activity of rituximab in extranodal marginal zone B-cell lymphoma of MALT type. *Blood* 2003;102(8):2741–5.
- [78] Hammel P, Haioun C, Chaumette MT, Gaulard P, Divine M, Reyes F, et al. Efficacy of single-agent chemotherapy in low-grade B-cell mucosa-associated lymphoid tissue lymphoma with prominent gastric expression. *J Clin Oncol* 1995;13(10):2524–9.
- [79] Jager G, Neumeister P, Brezinschek R, Hinterleitner T, Fiebigler W, Penz M, et al. Treatment of extranodal marginal zone B-cell lymphoma of mucosa-associated lymphoid tissue type with cladribine: a phase II study. *J Clin Oncol* 2002;20(18):3872–7.
- [80] Voulgarelis M, Giannouli S, Anagnostou D, Tzioufas AG. Combined therapy with rituximab plus cyclophosphamide/doxorubicin/vincristine/prednisone (CHOP) for Sjogren's syndrome-associated B-cell aggressive non-Hodgkin's lymphomas. *Rheumatology* 2004;43(8):1050–3.
- [81] Voulgarelis M, Giannouli S, Tzioufas AG, Moutsopoulos HM. Long term remission of Sjogren's syndrome associated aggressive B cell non-Hodgkin's lymphomas following combined B cell depletion therapy and CHOP (cyclophosphamide, doxorubicin, vincristine, prednisone). *Ann Rheum Dis* 2006;65(8):1033–7.
- [82] Voulgarelis M, Petroutsos G, Moutsopoulos HM, Skopouli FN. 2-Chloro-2'-deoxyadenosine in the treatment of Sjogren's syndrome-associated B cell lymphoproliferation. *Arthritis Rheum* 2002;46(8):2248–9.